

# Tinea Incognito - Epilogue of Inadequate Diagnostics And Therapy

Srna G. Božić<sup>1,2</sup>, Nataša Z. Milošević<sup>1,3</sup>, Aleksandra S. Bukvić Šajinović<sup>1,4</sup>, Dunja M. Vesković<sup>1,5</sup>, Ljuba M. Vujanović<sup>1,5</sup>

<sup>1</sup> Faculty of Medicine, University of Novi Sad, Novi Sad, Serbia

<sup>2</sup> Polyclinic „dr Brana Kovačević“, Novi Sad, Srbija

<sup>3</sup> Office „Rea 2“, Novi Sad, Srbija

<sup>4</sup> Polyclinic „NOVAKOV i sar.“, Novi Sad, Srbija

<sup>5</sup> Clinic for Dermatovenereology, Clinical Center of Vojvodina, Novi Sad, Serbia

## SUMMARY

**Introduction:** Tinea incognito is a form of the disease Tinea corporis, and it is a superficial fungal skin infection caused by dermatophytes. It occurs in cases when clinical signs of the condition are misdiagnosed, and treatment with local and/or systemic corticosteroid therapy is administered, leading to the advancement of disease with an altered clinical status that persists for a long time and requires prolonged systemic treatment.

**Case Report:** We present a 71-year-old patient who came for examination due to skin changes that appeared a year ago. The changes were localized on the extensors of the forearm, flexor side of the wrist joint, and lower part of the thighs in the form of erythematous and scaly plaques, partially merged on the forearm, and individual, annular erythematous plaques with pronounced peripheral borders and signs of central regression. The patient was diagnosed with Psoriasis vulgaris. He was treated with systemic retinoids (acitretin, Neotigason caps a 25 mg, Teva B.V.) over the course of 5 months, and with topical corticosteroids (mometazon, Elocom 1 mg/g mast, Organon Heist B.V.) over the course of ten months. Due to the worsening of the local findings, the patient was referred to the Clinic of Dermatovenereology Diseases of the Clinical Center of Vojvodina, where a preliminary diagnosis of Tinea incognito was established. A mycological examination was performed, during which the direct mycological findings were positive. The patient was treated with topical (terbinafine, Lamisil 10 mg/g krem, GSK Consumer Healthcare SARL) and systemic (flukonazol, Diflucan caps a 50 mg, Fareva amboise) antifungals, after which there was complete regression of changes on the skin.

**Conclusion:** Tinea incognito is a superficial fungal skin infection, which occurs due to inadequate therapy prescribed for Tinea corporis. Fungal infections of the skin and skin adnexa are relatively common. Diagnosis is established through a detailed medical history, physical examination, and mycological examination. Timely application of topical and/or systemic antifungals leads to complete regression of skin changes. When the disease goes unrecognized and is treated with inadequate medications, it may progress into a distinct (atypical) form known as Tinea incognito.

**Keywords:** Dermatophytosis, Skin Infections, Diagnosis, Corticosteroids, Antifungals

Corresponding author:

Assistant Professor Ljuba M. Vujanović, MD, PhD

Specialist in Dermatovenereology

Dermatovenereology department, Faculty of Medicine, University of Novi Sad, Hajduk Veljkova 3, 21000 Novi Sad, Serbia

E-mail: ljuba.vujanovic@mf.uns.ac.rs

## INTRODUCTION

Tinea incognito is a form of the condition Tinea corporis, which occurs due to unrecognized fungal infection of the skin and due to inadequate and untimely diagnosis and treatment. Tinea corporis is a common, superficial fungal infection of non-hairy skin of the body and extremities caused by dermatophytes [1]. The diagnosis is established based on medical history, which includes epidemiological surveys, physical examination, and mycological examination (direct microscopy and culture for dermatophytes). Tinea incognito typically occurs due to the initiation of inadequate therapy without prior mycological examination, most commonly with topical corticosteroid preparations or a combination of topical agents (keratolytics, corticosteroids).

## CASE REPORT

We hereby present a 71-year-old patient who came to the Clinic of Dermatovenereology Diseases of the Clinical Center of Vojvodina due to skin changes on the forearms and upper legs that appeared a year ago. Upon reviewing the medical records, initially, the skin lesions manifested as erythematous plaques with whitish and adherent scaling, localized on the extensor of the right forearm, accompanied by mild itching. Over the next few days, identical lesions appeared on the left forearm and lower part of the upper legs. In the personal medical history, the patient reports no prior skin

changes, has been diagnosed with diabetes mellitus for the past 5 years, and is being treated with oral antidiabetic medications (metformin, Gluformin tbl a 1000 mg, Hemofarm). There is no family history of skin disorders.

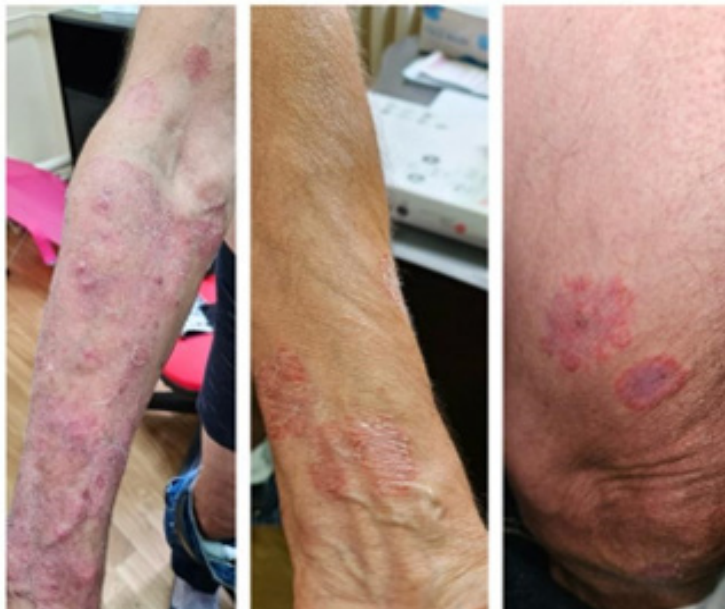The epidemiological history is positive. During the examination, the patient provided information that their pet (dog) had been shedding hair in patches and had been treated by a veterinarian.

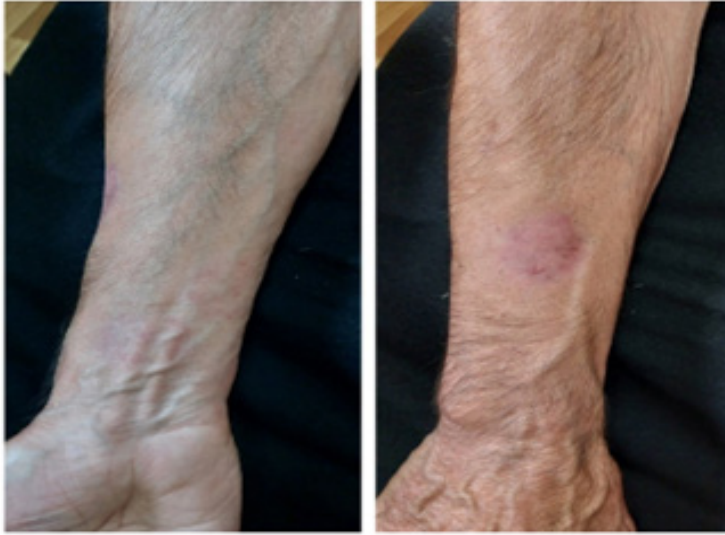The dermatologist treated the patient for Psoriasis vulgaris with oral retinoids (acitretin, Neotigason caps a 25 mg, Teva B.V.) for 5 months. The treatment was discontinued due to adverse reactions to the medication and inadequate therapeutic response. In addition to oral retinoid therapy, topical corticosteroid creams (mometazon, Elocom 1 mg/g mast, Organon Heist B.V.) were used for 10 months without improvement in the local findings.

On the initial examination at the Clinic of Dermatovenereology Diseases, the patient had changes in the form of well-defined, erythematous and scaly plaques, partially merging on the entire extensor of the right forearm. On the flexor side of the wrist and the lower part of the upper legs, erythematous and scaly annular plaques were present, with pronounced borders and signs of central regression (Figure 1).

A mycological examination of the skin lesion was conducted, and the direct mycological finding was positive. Systemic therapy with fluconazole (Diflucan caps a 50 mg, Fareva amboise) at a dose of 50 mg daily

**Figure 1.** Skin changes in the form of erythemasquamous plaques, partially confluent and single, annular erythematous plaques with pronounced peripheral edges and central signs of regression. The changes are a reflection of the ten-month application of topical corticosteroid therapy.





**Figure 2.** Changes on the skin in regression one month after starting systemic therapy with fluconazole.

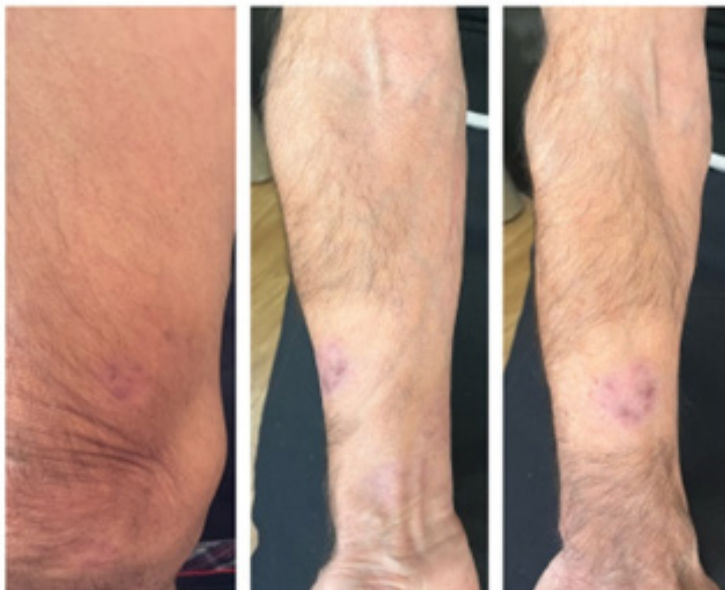
was initiated along with topical application of terbinafine (Lamisil 10 mg/g cream, GSK Consumer Healthcare SARL) and local hair removal. The subsequently received culture for dermatophytes and yeast, after 14 days of cultivation, returned negative. Significant regression of changes on the skin was observed after one month of therapy. Discreet, pale erythematous plaques, predominantly on the extensor of the forearms have remained. Itching was less intense. Liver enzyme levels were within reference ranges before initiating therapy and during therapy with systemic antifungals.

Systemic and local treatment with antifungals was conducted over the course of 8 weeks, and it was accompanied by gradual regression of the skin lesions. Three weeks after

the treatment ended, a complete resolution of changes on the skin was achieved (Figure 3). The patient consented to his case being published anonymously in the scientific journal Hospital Pharmacology.

Tinea incognito is a condition described over 50 years ago but remains relevant due to misdiagnosis and irrational use of topical glucocorticoids as recommended by selected physicians or pharmacists [2]. Although it represents a form of superficial dermatosis, the clinical status can be altered due to inadequate treatment choices.

Dermatophytoses are common fungal skin infections that are widely spread. They are caused by fungi belonging to the genera *Trichophyton*, *Epidermophyton*, or *Microspo-*



**Figure 3.** Full regression of changes on the skin after an 8-week therapy with antifungals

*rum*. Depending on the source of infection, they are classified as anthropophilic, zoophilic, or geophilic dermatophytes [1]. These types of fungi have a tendency to form molecular bonds with keratin and use it as a food source, colonizing the *stratum corneum* of the epidermis, hair, nails, and keratinized tissues of animals. They are transmitted through direct contact with infected human or animal skin. The incubation period is 1-3 weeks. Clinically, they manifest as single or multiple annular plaques with a pale or yellowish-brown center and an active erythematous border. Vesicles, papules, or pustules may be distributed along the active peripheral border. The central area shows signs of regression due to fungal elimination and resolution of the inflammatory response. Polycyclic forms of the disease, resulting from peripheral spreading and merging of individual lesions, are not uncommon [1]. Itching is often present. The clinical status in our patient matched this description (Figure 1).

Tinea incognito can mimic a wide range of dermatoses [3,4]. Therefore, it should be considered differentially in all chronic, erythematous, and erythematous-squamous skin lesions that do not respond adequately to local therapy.

Differential diagnosis should primarily differentiate from psoriasis, which was initially considered as the working diagnosis in this patient. Psoriasis primarily occurs in predilection areas (elbows, knees, scalp), with the majority of cases manifesting the first signs of the condition by the age of 35, which was not the case with our patient. Additionally, inadequate therapeutic response to topically applied corticosteroids and systemically administered retinoids should prompt reconsideration of the initial working diagnosis. Differential diagnosis should also consider other fungal and bacterial skin diseases, especially those with an erythematous and squamous clinical presentation (impetigo, candidiasis, pityriasis versicolor, and syphilis).

Eczemas like nummular and seborrheic eczema can pose challenges in diagnosis, as they typically respect their predilection sites, the seborrheic regions, which is not the case with our patient. In establishing the final diagnosis for our patient, the information that was significant was that there was no family history of skin diseases, the patient's age, the onset of skin changes in his seventies, and the medical history of comorbidity (diabetes mel-

litus). Of course, the subsequently obtained positive epidemiological survey data were crucial for suspecting fungal infection.

Difficulty in diagnosing fungal infections can sometimes result from the unavailability of laboratories where mycological examination of material obtained by scraping skin lesions can be performed. Mycological examination (direct preparation and culture for dermatophytes) can reveal fungal elements - branched or septate hyphae. Anamnestic data regarding the onset and spread of skin changes and a positive epidemiological survey may be sufficient to raise suspicion of fungal infection. Another challenge encountered in practice is the frequent occurrence of false-negative results in mycological examinations, leading the physician to easily dismiss the possibility of this diagnosis. A procedure that is often overlooked but can be useful is dermoscopy (whitish scales extending outward at the active border) [2].

Treating dermatophytoses can be challenging. Recurrences are common, as well as refractoriness to therapeutic procedures. Treating Tinea incognito does not differ from treating Tinea corporis, with the addition that it is necessary to exclude local or systemic corticosteroids and other immunosuppressive agents from the treatment. Antifungals are medications used to treat dermatophytoses, administered either topically or systemically [1]. Systemic antifungals can cause adverse effects such as nausea, vomiting, or bloating. Monitoring liver enzyme levels is necessary before starting and during therapy with most antifungal agents.

In addition to medication therapy, implementing general measures such as wearing appropriate cotton clothing and footwear made of natural materials is necessary for the prevention and treatment of dermatophytoses. Veterinary examination and treatment are essential not only for pets (dogs, cats) but also for all domestic animals that may serve as a source of infection (cattle). It is important to emphasize that increasingly more often, the patients initiate local corticosteroid therapy on their own or upon the advice of a pharmacist, which contributes to masking the typical clinical status [5].

## CONCLUSION

Tinea incognito represents a chronic fungal

skin infection resulting from inadequate use of local and/or systemic glucocorticoids. It is becoming an increasingly common issue in practice, primarily due to the failure to recognize the typical clinical status by the primary care physician and/or dermatologist and initiating therapy with topical corticosteroids or self-initiated corticosteroid treatment for skin changes based on a recommendation made by a pharmacist.

## CONFLICT OF INTEREST

All authors declare no conflict of interest.

## REFERENCES

1. Karadaglic Dj. Dermatologija. Vojnoizdavački zavod Beograd 2016. pp 2091-105.
2. Arenas R, Moreno-Coutiño G, Vera L, Welsh O. Tinea incognito. *Clinics in dermatology*. 2010 Mar 1;28(2):137-9.
3. Nowowiejska J, Baran A, Flisiak I. Tinea incognito—A great physician pitfall. *Journal of Fungi*. 2022 Mar 18;8(3):312.
4. Dhaher S. Tinea incognito: Clinical perspectives of a new imitator. *Dermatology Reports*. 2020 Jun 6;12(1).
5. Diruggiero D. Successful management of psoriasis and treatment-induced tinea incognito: a case report. *The Journal of Clinical and Aesthetic Dermatology*. 2020 Sep;13(9 Suppl 1):S21.

## Tinea Incognito - epilog neadekvatne dijagnostike i terapije

Srna G. Božić<sup>1,2</sup>, Nataša Z. Milošević<sup>1,3</sup>, Aleksandra S. Bukvić Šajinović<sup>1,4</sup>, Dunja M. Vesković<sup>1,5</sup>, Ljuba M. Vujanović<sup>1,5</sup>

<sup>1</sup> Medicinski fakultet, Univerziteta u Novom Sadu, Novi Sad, Srbija

<sup>2</sup> Poliklinika „dr Brana Kovačević“, Novi Sad, Srbija

<sup>3</sup> Ordinacija „Rea 2“, Novi Sad, Srbija

<sup>4</sup> Poliklinika „NOVAKOV i sar.“, Novi Sad, Srbija

<sup>5</sup> Klinika za kožno-venerične bolesti, Klinički centar Vojvodine, Novi Sad, Srbija

### KRATAK SADRŽAJ

**Uvod:** Tinea incognito je oblik bolesti Tinea corporis, a predstavlja površinsku gljivičnu infekciju kože uzrokovanu dermatofitima. Javlja se kada klinički znaci bolesti nisu prepoznati, te se primenjuje terapija lokalnim i/ili sistemskim kortikosteroidima, što dovodi do napredovanja bolesti sa promenjenim kliničkim statusom koji traje dugo i zahteva produženo sistemsko lečenje.

**Prikaz slučaja:** Prikazujemo slučaj 71-godišnjeg pacijenta koji je došao na pregled zbog promena na koži koje su se pojavile pre godinu dana. Promene su bile lokalizovane na ekstenzornim delovima podlaktice, fleksorskoj strani zglobova i donjem delu butina u vidu eritematoznih i ljuskavih plakova, delimično spojenih na podlaktici, i pojedinačnih, prstenastih eritematoznih plakova sa izraženim perifernim rubovima i znacima centralne regresije. Pacijent je prvobitno dijagnostikovao kao Psoriasis vulgaris. Tretiran je sistemskim retinoidima (acitretin, Neotigason caps a 25 mg, Teva B.V.) tokom 5 meseci i topikalnim kortikosteroidima (mometazon, Elocom 1 mg/g mast, Organon Heist B.V.) tokom deset meseci. Zbog pogoršanja lokalnog nalaza, pacijent je upućen u kliniku za kožne i venerične bolesti Kliničkog centra Vojvodine, gde je postavljena radna dijagnoza Tinea incognito. Načinjeno je mikološko ispitivanje, direktni mikološki nalazi su bili pozitivni. Pacijent je tretiran topikalnim (terbinafine, Lamisil 10 mg/g krem, GSK Consumer Healthcare SARL) i sistemskim (flukonazol, Diflucan caps a 50 mg, Fareva amboise) antimikoticima, nakon čega je došlo do potpune regresije promena na koži.

**Zaključak:** Tinea incognito je površinska gljivična infekcija kože koja nastaje usled neadekvatne terapije propisane za Tinea corporis. Gljivične infekcije kože i njenih adneksa su relativno česte. Dijagnoza se postavlja na osnovu detaljne anamneze, fizičkog pregleda i mikološkog ispitivanja. Pravovremena primena topikalnih i/ili sistemskih antimikotika dovodi do potpune regresije promena na koži. Kada bolest ostane neprepoznata i tretira se neadekvatnom terapijom, može se razviti u atipični oblik poznat kao Tinea incognito.

**Ključne reči:** dermatofitoze, infekcije kože, dijagnoza, kortikosteroidi, antimikotici

Received: May 29, 2024

Accepted: July 9, 2024