

Sulfasalazine induced DRESS (Drug Reaction with Eosinophilia and Systemic Symptoms) Syndrome With Severe Acute Hepatitis - Case Report

Danilo D. Kuzman^{1,2}, Biljana P. Jeremić-Gajinov^{1,2}, Dunja M. Vesković^{1,2},
Sanja B. Jakovljević^{1,2}, Ljuba M. Vujanović^{1,2}

¹ Faculty of Medicine, University of Novi Sad, Novi Sad, Serbia

² Clinic of Dermatovenereology Diseases, University Clinical Center of Vojvodina, Novi Sad, Serbia

SUMMARY

Introduction: Drug Reaction with Eosinophilia and Systemic Symptoms Syndrome is a rare and severe form of drug induced delayed-type hypersensitivity reaction with mortality rate up to 10%. It usually manifests with skin rash, fever, lymphadenopathy, hematological abnormalities and involvement of one or more internal organs. Establishing the diagnosis is sometimes late due to variable clinical presentation. Current recommendations for therapy rely mainly on expert opinions, retrospective studies, case reports and series. Sulfasalazine was firstly synthesized in 1930 and is currently being prescribed for various inflammatory and rheumatic diseases.

Case report: We present a 45-year-old patient who was prescribed sulfasalazine tablets by a rheumatologist due to reactive arthritis. In the fourth week of therapy, he developed skin rash and fever up to 39.5°C. On admission, generalized maculopapular exanthema covering over 60% of the body surface area, edema of the lower eyelids and bilateral cervical and inguinal lymphadenomegaly were registered. Laboratory findings showed leukocytosis with significant eosinophilia, lymphocytosis, elevated bilirubin values, ALT <100 U/L, while ultrasonography of the upper abdomen confirmed hepatosplenomegaly. The patient was diagnosed with Drug Reaction with Eosinophilia and Systemic Symptoms Syndrome using RegiSCAR and J-SCAR diagnostic criteria and systemic therapy with methylprednisolone at a dose of 1.5 mg/kg and other supportive therapy was applied, which resulted in complete regression of the skin changes and normalization of laboratory values.

Conclusion: The authors would like to recall the occurrence of Drug Reaction with Eosinophilia and Systemic Symptoms Syndrome as a rare and potentially fatal drug reaction in which awareness of this disease is of key importance for early recognition. Identification of the offending drug followed by a prompt withdrawal and subsequent treatment is essential for decreasing disease related morbidity and mortality and thus we wish to familiarize the sulfasalazine prescribers with this syndrome.

Keywords: Drug Induced Hypersensitivity Syndrome, Severe Cutaneous Adverse Drug Reaction, Skin Rash, Hypereosinophilia, RegiSCAR scoring system, J-SCAR scoring system

Corresponding author:

Associate Professor Ljuba M. Vujanović, MD, PhD

Specialist in dermatovenereology

Faculty of Medicine, Hajduk Veljkova 3, 21000 Novi Sada, Serbia

E-mail: ljuba.vujanovic@mf.uns.ac.rs

INTRODUCTION

Drug Reaction with Eosinophilia and Systemic Symptoms (DRESS) syndrome or Drug Induced Hypersensitivity Syndrome (DIHS) is a severe form of drug induced delayed-type hypersensitivity reaction with significant morbidity and mortality. It is usually manifested with skin rash, fever, lymphadenopathy, hematological abnormalities and involvement of one or more visceral organs [1]. Despite the treatment, the mortality rate of DRESS can range from 3.8% up to 10% and main causes of fatal outcome include fulminant hepatitis and liver necrosis. The estimated incidence of DRESS syndrome is more than 1 case per 10 000 drug exposures, but the actual incidence may be even higher depending on the offending drug and because many cases probably remain inadequately diagnosed and treated [2].

Establishing the diagnosis of DRESS syndrome may be challenging and is sometimes late due to variable clinical presentation. To aid in clinical diagnosis, the original diagnostic criteria proposed by Bocquet et al are now replaced by the European Registry of Severe Cutaneous Adverse (Drug) Reactions (RegiSCAR) scoring system and Japanese Research Committee on Severe Cutaneous Adverse (Drug) Reactions (J-SCAR) diagnostic criteria [3, 4, 5]. Current recommendations for therapy rely mainly on expert opinions, retrospective studies, case reports and series [6].

Sulfasalazine was firstly synthesized in 1930 and is currently being prescribed for various inflammatory and rheumatic diseases because of its anti-inflammatory properties. A review article from 2016 conducted by Jas-

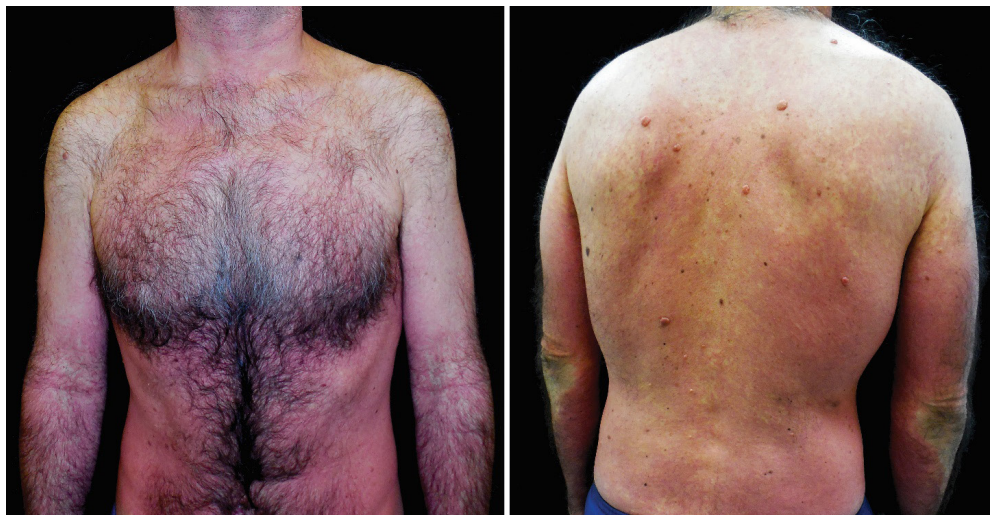
meen et al registered nearly 50 independent case reports of sulfasalazine induced DRESS syndrome from 1990 to 2015, which diagnosis was made by the use of RegiSCAR scoring system [7]. The patient gave a written consent for the anonymous publication of this case report.

CASE REPORT

We present a 45-year-old patient who developed reactive arthritis after recurrent urethritis, which is why he was prescribed sulfasalazine tablets at a dose of 500mg 3 times a day by a rheumatologist. In the fourth week of therapy, skin rash appeared on the neck, chest and back, accompanied by a subjective feeling of itching and fever between 38 and 39.5°C. On his own initiative, he stopped the use of sulfasalazine tablets. He was examined by a general practitioner on an outpatient basis when elevated bilirubin and transaminase values were laboratory verified, and was referred to a dermatologist who indicated hospital treatment. The patient denied other illnesses as well as regular or occasional use of other medications.

On admission, the patient was in a stable general condition, cardiopulmonary function was within normal limits; subfebrile (37.5°C) and subicteric. Bilateral lymphadenomegaly of the cervical and inguinal lymph nodes was registered at physical examination without other clinical signs. He denied complaints from the respiratory, cardiovascular, digestive, urinary and other organ systems. A generalized maculopapular exanthema cov-

Figure 1. Maculopapular skin rash, anterior and posterior side of the trunk



ering over 60% of the body surface area was registered, most prominent on the skin of the trunk, upper and lower extremities, with individual erythematous macules on the skin of the palms and soles (Figures 1, 2, 3 and 4). The skin changes spared the face and capillitium; there was edema of the lower eyelids, while the visible mucous membranes were without pathological changes (Figure 5).

Performed laboratory tests demonstrated leukocytosis ($13.4 \times 10^9/L$) with significant eosinophilia ($24.6\% - 3.3 \times 10^9/L$), lymphocytosis ($64.9\% - 8.7 \times 10^9/L$), while peripheral blood smear showed a pair of activated lymphocytes without the presence of atypical ones. Moreover, slightly elevated C-reactive protein (19.6 mg/L), elevated bilirubin (total $80.1 \mu\text{mol/L}$, direct $72.0 \mu\text{mol/L}$), multiple elevated transaminase values (ALT 771 U/L , AST 233 U/L , GGT 152 U/L), elevated LDH (564 U/L) and mildly decreased total serum proteins (54 g/L) were also detected. The blood sugar was slightly elevated (7.5 mmol/L), parameters of the hemostasis mechanism, including prothrombin time, were within reference values. Renal studies showed elevated values of urea (8.5 mmol/L), creatinine ($145 \mu\text{mol/L}$) and acidum uricum ($415 \mu\text{mol/L}$), while electrolytes were within normal limits. Qualitative urine analysis confirmed the presence of protein, bilirubin and increased urobilinogen, while the estimated glomerular filtration rate, creatinine clearance and 24h proteinuria were normal. Immunology findings including RF, C3 and C4 complement components, IgG, IgA, and IgM class immunoglobulins, ANA on primate liver and Hep-2 cells, and ANCA were within reference range or negative. Serology for Adenovirus, Epstein-Barr virus, Coxsackie B virus, Herpes simplex virus type 1 and 2, HIV, Hepatitis B and C virus was negative. Enterobacter spp.

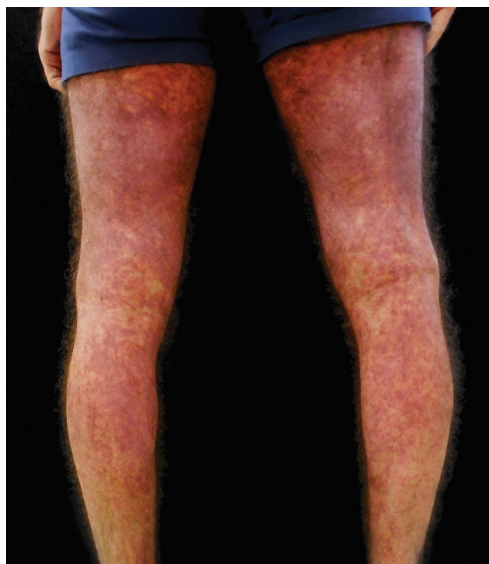

Figure 2. Maculopapular skin rash, posterior side of the legs

was cultured from the throat smear, while nose, throat, urine and blood cultures were negative.

X-ray of the lungs and heart was normal, and ultrasonography of the upper abdomen confirmed hepatomegaly (17 cm in the midclavicular line) and splenomegaly (dimensions $14 \times 7 \text{ cm}$), while no pathological changes in the kidneys were described.

The patient was diagnosed with DRESS syndrome with involvement of the skin and liver, and systemic therapy with corticosteroids (methylprednisolone at a dose of 1.5 mg/kg), antihistamines and antibiotics (ceftriaxone according to the antibiogram) was prescribed, along with supportive rehydration therapy with crystalloid solutions, hepatoprotective and local indifferent therapy with emollients. The dose of corticosteroids was gradually reduced with the transfer to oral prednisone therapy at a dose of 0.5 mg/kg one month after introduction. Corticosteroid therapy was completely stopped after a total of 3

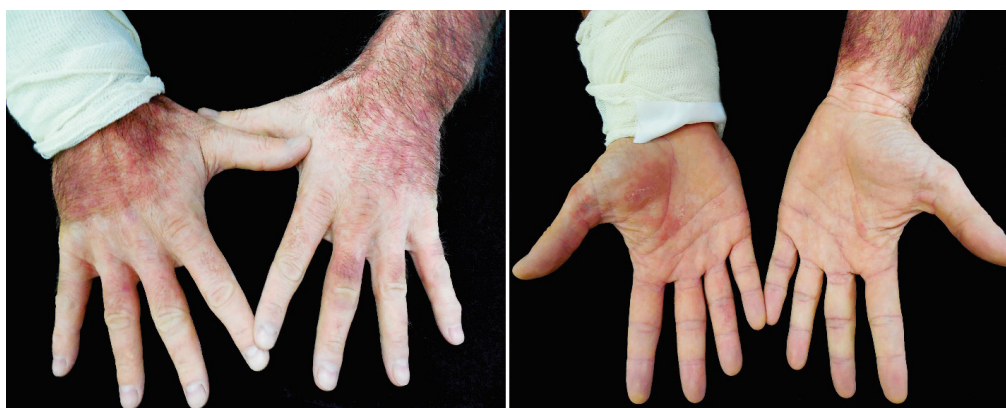

Figure 3. Maculopapular skin rash - dorsal side of the hands, erythematous macules - palmar side of the hands

Figure 4. Skin eruption on the trunk, detail

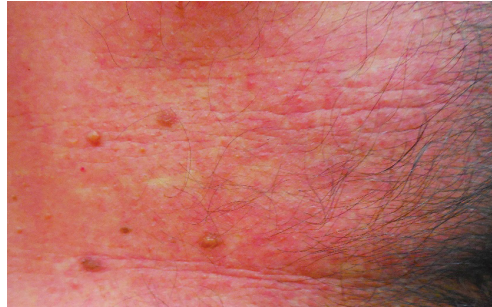
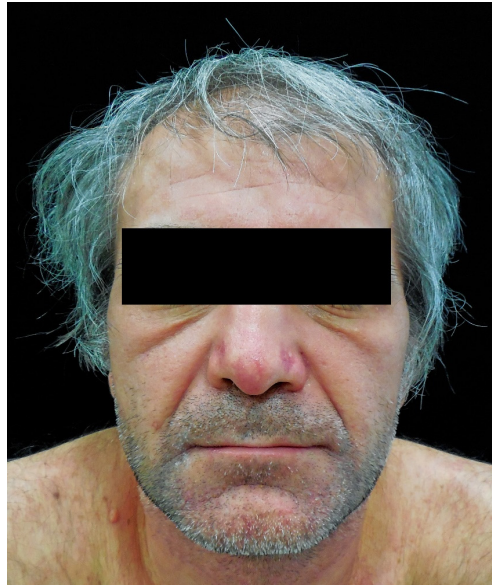
Figure 5. Edema of the lower eyelids, skin eruption sparing the face



months, which resulted in complete regression of skin lesions and normalization of laboratory values without recurrence of the disease during a 2-year follow-up period.

DISCUSSION

DRESS syndrome is classified as Severe Cutaneous Adverse (Drug) Reaction (SCAR) together with other entities that include mainly Stevens Johnson Syndrome, Toxic Epidermal Necrolysis (Lyell Syndrome) and Acute Generalized Exanthematous Pustulosis [8].

DRESS syndrome develops later than most other immunologically mediated skin reactions and usually 2 to 6 weeks after drug initiation, which was also the case in our patient in the 4th week of therapy. Drugs most commonly associated with DRESS syndrome include allopurinol, anticonvulsants (carbamazepine, phenobarbital, phenytoin, lamotrigine), antimicrobials (minocycline, vancomycin, sulfamethoxazole-trimethoprim, dapsone) and antiretrovirals (abacavir, nevirapine). Sul-

fasalazine has also been recognized as an causing drug, while not so common compared to others [9].

Clinically, DRESS syndrome manifests with fever, lymphadenopathy, hematologic abnormalities, systemic involvement and cutaneous eruption with different manifestation forms, most commonly maculopapular rash and facial edema, which was also the case in our patient, but other cutaneous lesions such as pustules, purpura, infiltrated plaques, blisters, targetoid lesions, urticarial lesions, an exfoliative dermatitis, eczema-like lesions, and lichenoid lesions can also be detected. Most commonly affected visceral organs include liver, kidney and lungs in a descending order, but pancreas and other gastrointestinal organs, heart and nervous system can also be involved [6].

The diagnosis of DRESS syndrome is established by correlation of clinical and laboratory findings with the aid of previously described different sets of diagnostic criteria [10].

The RegiSCAR criteria requires at least 3 of the following 7 characteristics: 1. Acute skin eruption, 2. Fever $>38^{\circ}\text{C}$, 3. Lymphadenopathy at 2 sites at least, 4. Involvement of at least 1 internal organ, 5. Lymphocytosis ($>4 \times 10^9/\text{L}$) or lymphocytopenia ($<1.5 \times 10^9/\text{L}$), 6. Blood eosinophilia ($>10\%$) and 7. Thrombocytopenia ($<120 \times 10^9/\text{L}$). Our patient met the first 6 criteria with the exception of platelet count which was normal. In addition, RegiSCAR scoring system classifies DRESS syndrome into four categories depending on the final score: <2 no case, 2-3 possible case, 4-5 probable case, >5 definite case. Since our patient had lymphadenopathy at 2 sites, peripheral eosinophilia $<1.5 \times 10^9/\text{L}$, extent of cutaneous eruption $<50\%$ of body surface area, cutaneous eruption suggestive of DRESS syndrome and involvement of liver, that classified our case as definite with a total score of 6 [4, 11].

The J-SCAR criteria includes the following features: 1. Maculopapular eruption developing <3 weeks after commencing with a limited number of drugs, 2. Prolonged clinical manifestations 2 weeks after discontinuation of the causative drug, 3. Fever $<38^{\circ}\text{C}$, 4. Liver abnormalities (ALT $<100 \text{ U/L}$) or other organ involvement as defined according to a study conducted by Chen et al, 5. Leukocyte abnormalities (leukocytosis $<11 \times 10^9/\text{L}$ or atypi-

cal lymphocytosis <5% or eosinophilia <1.5 $\times 10^9/L$), 6. Lymphadenopathy and 7. HHV-6 reactivation. The presence of all 7 criteria is required for the diagnosis of a typical DRESS syndrome, while the presence of the first 5 criteria is classified as atypical DRESS syndrome. Our patient met the first 6 criteria but PCR analysis for HHV-6 was not available, which classified our case as atypical [5, 12, 13].

Although causing drugs can potentially affect any of the previously mentioned organ systems in the DRESS syndrome, it has been found that certain medications have a predilection for specific organs – allopurinol and carbamazepine are associated with increased risk of renal involvement, phenytoin with hepatic, dapsone with both hepatic and renal and minocycline with hepatic, pulmonary and cardiac involvement. The most frequently affected visceral organ in the DRESS syndrome is the liver with varying degrees of hepatitis and increase in the liver enzymes and it can be accompanied with hepatosplenomegaly, which was also the case in our patient [14].

It had been previously reported that sulfasalazine was associated with severe acute hepatitis (ALT <10x the upper limit) in women in the second to fourth decade of life [15]. This data is in accordance with our case and present reports where sulfasalazine was associated with mainly liver involvement and where transaminases were found to increased ten times compared to normal values. The second most often affected organ in sulfasalazine induced DRESS syndrome is the kidney, but although our patient had elevated serum creatinine and urea levels, we didn't classify it as renal involvement since estimated glomerular filtration rate, creatinine clearance and 24h proteinuria were normal. The cases of lung and cardiac dysfunction in sulfasalazine induced DRESS syndrome have also been described [7, 16]. The authors did not notice any reports of other organ involvement such as central nervous system when reviewing the available literature on sulfasalazine induced DRESS syndrome.

There is an insufficient number of prospective studies that address the treatment of DRESS syndrome and current recommendations for therapy rely mainly on expert opinions, retrospective studies, case reports and series. Identification and prompt withdrawal of the causative medication is of key importance but it can be challenging bearing in mind the

long latency from the first drug exposure to the onset of DRESS syndrome [6]. Since there is currently no test that can determine the causing drug during the active phase of the disease, the physician has to recognize potential triggering medications based on patient's medical history. Sulfasalazine is considered to pose a very high risk as reported by Agier et al [1, 17].

Given the nature of prolonged clinical course of DRESS syndrome, withdrawal of the suspected drug will not result in immediate improvement [6]. It is recommended to include a multidisciplinary team composed of appropriate specialists when treating this syndrome since it can affect various organ systems [1]. Currently, the most widely accepted treatment is early administration of systemic corticosteroids at a minimum dose of 1 mg/kg of prednisone or equivalent, with gradual tapering off in a period of 3 to 6 months in order to avoid relapses [2]. Schunkert et al recommend treatment with intravenous methylprednisolone at 1 mg/kg and potentially even 1.5 mg/kg depending on the severity of the disease since oral prednisone requires liver metabolism to convert into its active form [1]. We conducted this regimen with successful outcome and no relapses. Other treatment options described in the literature include methylprednisolone pulse therapy, high dose of intravenous immunoglobulin, cyclosporine or other immunosuppressive drugs, plasmapheresis etc. [18, 19].

CONCLUSION

In conclusion, we would like to recall the occurrence of DRESS syndrome as a rare and potentially fatal drug hypersensitivity reaction with mortality rate up to 10%. Awareness of this entity is of key importance for early recognition and establishment of the proper diagnosis using clinical criteria, laboratory values and standardized scoring systems. Identification of the causing drug followed by a prompt withdrawal and subsequent treatment is essential for decreasing disease related morbidity and mortality in which physicians must be familiar with its common culprit medications. We wish to familiarize sulfasalazine prescribers with this syndrome and to encourage clinicians to further report cases of DRESS.

CONFLICT OF INTEREST

All authors declare no conflict of interest.

REFERENCES

- Schunkert EM, Divito SJ. Updates and insights in the diagnosis and management of DRESS syndrome. *Curr Dermatol Rep*. 2021;10:192-204.
- Calle AM, Aguirre N, Ardila, JC, Villa RC. DRESS syndrome: A literature review and treatment algorithm. *World Allergy Organ J*. 2023;16(3):100673.
- Bocquet H, Bagot M, Roujeau JC. Drug-induced pseudolymphoma and drug hypersensitivity syndrome (drug rash with eosinophilia and systemic symptoms: DRESS). *Semin Cutan Med Surg*. 1996;15(4):250-7.
- Kardaun SH, Sidoroff A, Valeyrie-Allanore L, Halevy S, Davidovici BB, Mockenhaupt M, Roujeau JC. Variability in the clinical pattern of cutaneous side-effects of drugs with systemic symptoms: does a DRESS syndrome really exist? *Br J Dermatol*. 2007;156(3):609-11.
- Shiohara T, Inaoka M, Kano Y. Drug-induced hypersensitivity syndrome (DIHS): a reaction induced by a complex interplay among herpesviruses and antiviral and antidrug immune responses. *Allergol Int*. 2006;55:1-8.
- Cardones AR. Drug reaction with eosinophilia and systemic symptoms (DRESS) syndrome. *Clin Dermatol*. 2020;38(6):702-11.
- Jasmeen PK, Varma S, Kalra H, Vohra K. Sulfasalazine induced DRESS syndrome: a review of case reports. *BJMMR*. 2016;11(7):1-11.
- Duong TA, Valeyrie-Allanore L, Wolkenstein P, Chosidow O. Severe cutaneous adverse reactions to drugs. *The Lancet*. 2017; 390(10106):1996-2011.
- Valeyrie-Allanore L, Obeid G, Revuz J. Drug Reactions. In: Bologna JL, Schaffer JV, Cerroni L, eds. *Dermatology*. 4th ed. Philadelphia: Elsevier Saunders; 2018. p.348-75.
- Dong-Hyun K, Young-Il K. Comparison of diagnostic criteria and determination of prognostic factors for drug reaction with eosinophilia and systemic symptoms syndrome. *Allergy Asthma Immunol Res*. 2014;6(3):216-21.
- Kardaun SH, Sekula P, Valeyrie-Allanore L, Liss Y, Chu CY, Creamer D, Sidoroff A, Naldi L, Mockenhaupt M, Roujeau JC. Drug reaction with eosinophilia and systemic symptoms (DRESS): An original multisystem adverse drug reaction. Results from the prospective RegiSCAR study. *Br J Dermatol*. 2013;169(5):1071-80.
- Shiohara T, Iijima M, Ikezawa Z, Hashimoto K. The diagnosis of a DRESS syndrome has been sufficiently established on the basis of typical clinical features and viral reactivations. *Br J Dermatol*. 2007;156:1083-84.
- Chen YC, Chiu HC, Chu CY. Drug reaction with eosinophilia and systemic symptoms: a retrospective study of 60 cases. *Arch Dermatol*. 2010;146:1373-9.
- Husain Z, Reddy BY, Schwartz RA. DRESS syndrome: Part I. Clinical perspectives. *J Am Acad Dermatol*. 2013;68(5):693.e1-14.
- Fernando SL, Henderson CJ, O'Connor KS. Drug-induced hypersensitivity syndrome with superficial granulomatous dermatitis - a novel finding. *Am J Dermatopathol*. 2009;31:611-13.
- Bourgeois GP, Cafardi JA, Groysman V, Pamboukian SV, Kirklin JK, Andea AA, Lauren C, Hughey LC. Fulminant myocarditis as a late sequelae of DRESS-2 cases. *J Am Acad Dermatol*. 2011;65(4):889-890.
- Agier MS, Boivin N, Maruani A, Giraudeau B, Gouraud A, Haramburu F, Jean Pastor MJ, Machet L, Jonville-Bera AP. Risk assessment of drug-induced drug reaction with eosinophilia and systemic symptoms (DRESS) syndrome: a disproportionality analysis using the French Pharmacovigilance Database. *Br J Dermatol*. 2016;175(5):1067-9.
- Cabañas R, Ramírez E, Sendagorta E, Alamar R, Barranco R, Blanca-López N, Doña I, Fernández J, García-Núñez I, García-Samaniego J, López-Rico R, Marín-Serrano E, Mérida C, Moya M, Ortega-Rodríguez NR, Rivas Becerra B, Rojas-Perez-Ezquerria P, Sánchez-González MJ, Vega-Cabrera C, Vila-Albelda C, Bellón T. Spanish Guidelines for Diagnosis, Management, Treatment, and Prevention of DRESS Syndrome. *J Investig Allergol Clin Immunol*. 2020;30(4):229-53.
- Husain Z, Reddy BY, Schwartz RA. DRESS syndrome: Part II. Management and therapeutics. *J Am Acad Dermatol*. 2013;68(5):709.e1-9.

Sulfasalazinom indukovani DRESS (Drug Reaction with Eosinophilia and Systemic Symptoms) sindrom sa teškim akutnim hepatitisom - prikaz slučaja

Danilo D. Kuzman^{1,2}, Biljana P. Jeremić Gajinov^{1,2}, Dunja M. Vesković^{1,2},
Sanja B. Jakovljević^{1,2}, Ljuba M. Vujanović^{1,2}

¹ Medicinski fakultet, Univerzitet u Novom Sadu, Novi Sad, Srbija

² Klinika za kožno-venerične bolesti, Univerzitetski Klinički centar Vojvodine, Novi Sad, Srbija

KRATAK SADRŽAJ

Uvod: Drug Reaction with Eosinophilia and Systemic Symptoms sindrom je redak i težak oblik reakcije preosetljivosti kasnog tipa indukovane lekom sa stopom mortaliteta i do 10%. Ispoljava se obično osipom na koži, povišenom telesnom temperaturom, limfadenopatijom, hematološkim abnormalnostima i zahvatanjem jednog ili više unutrašnjih organa. S obzirom na raznolikost kliničku prezentaciju, dijagnoza se nekada postavi kasno. Aktuelne preporuke za terapiju se oslanjaju uglavnom na ekspertiska mišljenja, retrospektivne studije, prikaze i serije slučajeva. Sulfasalazin je prvobitno sintetisan 1930. godine i trenutno se propisuje za različite inflamatorne i reumatske bolesti.

Prikaz slučaja: Prikazujemo bolesnika starosti 45 godina kome su zbog reaktivnog artritisa prepisane sulfasalazin tablete od strane reumatologa. U četvrtoj nedelji terapije razvio je kožni osip i povišenu telesnu temperaturu do 39,5 °C. Prilikom prijema, registrovan je generalizovani makulopapulozni egzantem koji je zahvatao preko 60% površine tela, edem donjih očnih kapaka kao i bilateralna cervikalna i ingvinalna limfadenomegalija. U laboratorijskim nalazima potvrđena je leukocitoza sa signifikantnom eozinofilijom, limfocitoza, povišene vrednosti bilirubina, ALT <100 U/L, dok je ultrasonografijom gornjeg abdomena potvrđena hepatosplenomegalija. Bolesniku je postavljena dijagnoza Drug Reaction with Eosinophilia and Systemic Symptoms sindroma uz pomoć RegiSCAR and J-SCAR dijagnostičkih kriterijuma i ordinirana je sistemska terapija metilprednizolonom u dozi od 1,5 mg/kg, uz ostalu suportivnu terapiju što je rezultiralo kompletnom regresijom kožnih promena i normalizacijom laboratorijskih nalaza.

Zaključak: Autori žele da podsete na pojavu Drug Reaction with Eosinophilia and Systemic Symptoms sindroma kao retkog i potencijalno fatalnog oblika reakcije na lek pri kojoj je svest o ovoj bolesti od ključnog značaja za rano prepoznavanje. Prepoznavanje inkriminišućeg leka praćeno promptnom obustavom i adekvatnim lečenjem neophodno je za smanjivanje morbiditeta i mortaliteta povezanog sa ovom bolešću zbog čega želimo da upoznamo lekare koji propisuju sulfasalazin sa ovim sindromom.

Ključne reči: Drug Induced Hypersensitivity Syndrome, Severe Cutaneous Adverse Drug Reaction, kožni osip, hipereozinofilija, RegiSCAR sistem skorovanja, J-SCAR sistem skorovanja

Received: July 07, 2023

Accepted: July 28, 2023